

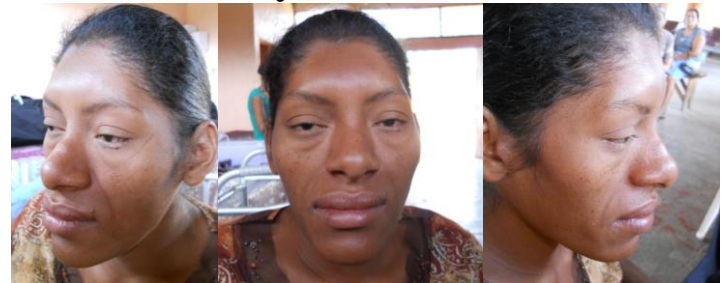Salud Juntos Winter 2011 Brigade to Punta Ocote



Friday 7 January 2011

Fin! Greetings from El Progreso. We finished the week on a high note, seeing 61 patients in a single half day. The theme of the morning seemed to be advanced disease as local diabetics, hypertensives, and elderly seemingly realized that this was their last chance to be evaluated. Here are some notable moments:

Case of the Day



This tall, 34-year-old diabetic female presented with right eye vision that was counting fingers only. We detected visual field restriction and proliferative diabetic retinopathy. She was referred to nearby San Pedro Sula for laser treatment. We also inquired about her prominent nose and jaw, coarse features, and height. Additional history revealed a pituitary tumor resected two years prior, consistent with acromegaly.



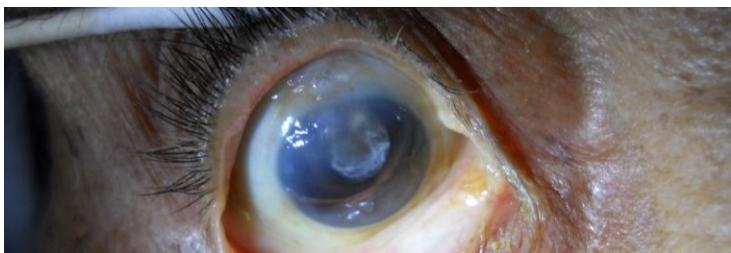
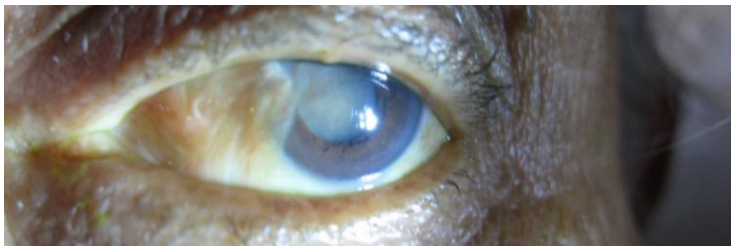
By wearing his stylish new sunglasses donated by ALERT, a Honduran boy becomes a positive role model for his younger brother.

Clinical Images



Shown here is a 43-year-old female with left vision loss following blunt head trauma as a teenager with a poor left red reflex. We found her to be 20/400 in that eye with a large, scarred choroidal rupture involving the entire macula.

Salud Juntos Staff of the Day



We felt surrounded by white cataracts today. A pair of representative cataracts are shown, accompanied by pterygium (top) and glaucoma (filtering bleb; bottom).



This 20-year-old young man sustained head trauma as a small child and presented with a turned-in right eye with 20/200 vision. Review of childhood pictures demonstrated a chronic monocular esotropia following the trauma.



His decreased right eye vision could not be corrected with glasses and is consistent with amblyopia. Fortunately, his left eye vision is 20/20. Left eye protection is a must, and elective strabismus surgery is an option to straighten his eyes and improve his appearance.



Janira Galeano was locally born and raised in Punta Ocote. She lives behind the clinic and her parents live across the street. She distributes meds to patients as a medical assistant in the main clinic pharmacy, but began working with Salud Juntos beginning with last year's Brigade.



She staffs the Taquilla (ticket office) window, where she is the first person to greet our patients. She feels the Brigades provide valuable general medicine and vision services to the community and notes a need for ENT also.

She has three sisters and two brothers and is the proud mother of two boys. Her hobbies include sewing. Of note, Janira also owns the dog now affectionately known as Jo'Nemesis.



Chicken of the Day



As chosen by Pat Broyles.

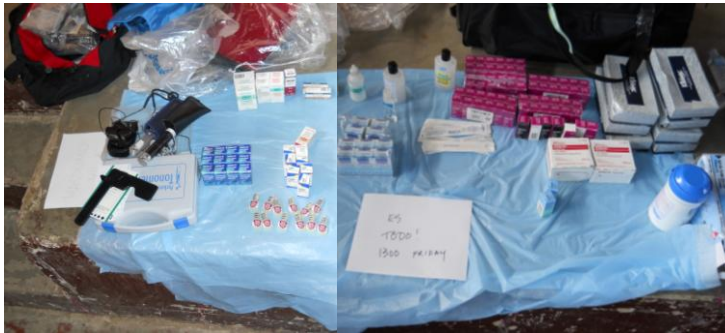Geotag of the Day



“The Dump”

N 15 degrees 07.000’

W 87 degrees 10.293’



This is what remained of our drops. There was a shortage of Patanol, Alphagan, and artificial tears in particular.

Friday Statistics

Of the 61 patients seen, 16 (26%) were men and 45 (74%) were women.

Age	Hyperopia	Emmetropia	Myopia
<= 40 yrs	8	0	2
>40	26	2	2

Diagnoses:

- 38 REFRACTIVE ERROR
- 30 DRY EYE
- 26 CATARACT
- 20 PTERYGIUM
- 18 ALLERGIC CONJUNCTIVITIS
- 8 TYPE 2 (NIDDM) WITHOUT RETINOPATHY
- 3 HYPERTENSIVE RETINOPATHY
- 2 CORNEAL SCAR
- 2 PRIMARY OPEN ANGLE GLAUCOMA
- 2 DRUSEN
- 1 PROLIFERATIVE DIABETIC RETINOPATHY
- 1 NON-PROLIFERATIVE DIABETIC RETINOPATHY
- 1 CLINICALLY-SIGNIFICANT MACULAR EDEMA
- 1 AMBLYOPIA
- 1 CHOROIDAL RUPTURE
- 1 PTOSIS
- 1 LENS-INDUCED GLAUCOMA
- 1 PHLYCTENULAR CONJUNCTIVITIS



Matthew Feng, MD, conducts the mariachis in a good night lullaby. A second year UA/UPHK resident in ophthalmology, Dr Feng attended medical school at the University of Pittsburgh, where he met his wife, Brenna, an Emergency Medicine Resident at the University of Arizona. Among his talents, Dr Feng is an accomplished musician, having competed at the National and International levels in piano recital. He also moonlights as an exterminator, taking call for the Tucson Insect Stammers.