

Salud Juntos Winter 2011 Brigade to Punta Ocote



Tuesday 4 January 2011

Tres Amigos Plus One



These four cousins lit up clinic today with their smiles and new, stylish sunglasses, courtesy of ALERT. Every child who attends the clinic is given sunglasses in this region where cataracts and pterygia are so prevalent, and the generous donations from ALERT make this possible.

I-test




Joe Miller, MD, uses a simplified, portable phoropter to determine the glasses prescription for the first near-sighted patient seen in this year's brigade. Unlike in the USA, in Honduras far-sightedness far exceeds near-sightedness.


Neutralizing Lenses in the Clinic (Poor man's lensmeter)

We found that a fair number of glasses had been separated from their bags, or the tags had fallen off. How do you know what the power of the specs are when there is no lensmeter?

Estimation! When a plus or magnifying lens is stacked on top of a equal minus lens, the two turn into a plain glass window and there is no magnification.




These glasses magnify the lines on the paper about 8 inches away.



This minus 4 lens takes away the magnification! The lenses are about plus four on top of the bifocal. Problem solved.

Follow-up Patient of the Day



This 47-year-old man was seen during last year's brigade. He had injured his left eye when he was a teenager, resulting in loss of the eye five years later and placement of a prosthesis. He is pictured with last year's note, which describes a concern for a rare inflammatory condition of his *uninjured* right eye called sympathetic ophthalmia. It is a frightening condition that develops in the uninjured eye, often years after the original injury. Unfortunately, it was clear at this visit that he has sympathetic ophthalmia and there was little that could be done.

#1 in Customer Service



Pat Broyles receives a hug from another satisfied patient.

Case of the Day



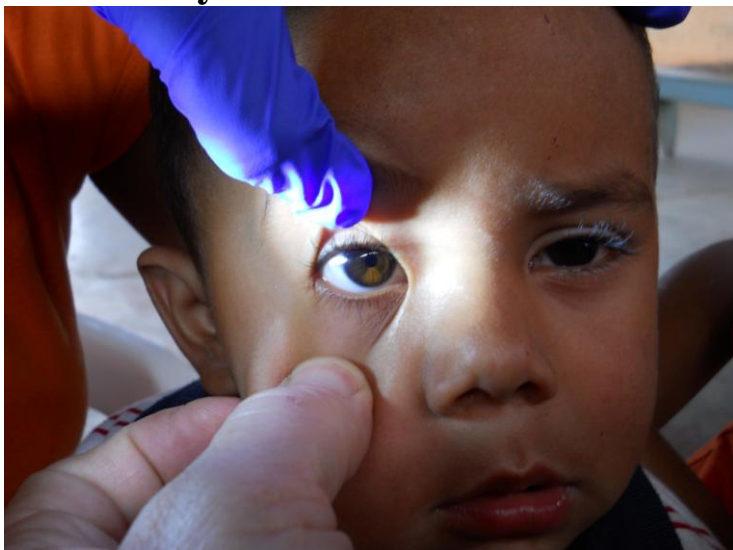This adorable 7-month-old girl was brought in by her concerned mother for turning in of her left eye essentially since birth. We found that she had difficulty looking to the sides, a low and symmetric amount of far-sightedness, and normal dilated retinal exam without masses or lesions. This was most consistent with congenital esotropia, which is an indication for surgery. She will receive a referral and we asked to see her back next year.

(Not) Lost in Translation



One of our first patients of the day was a mute gentleman with whom we anticipated difficulty communicating. However, we quickly realized that his inability to speak Spanish paired nicely with our inability to understand it! Here he is shown happily able to read his watch after receiving readers.

Clinical Mysteries



A 2-year-old boy presented with his mother and siblings, concerned for a change in iris color since birth. Retinoscopy and dilated retinal exam were within normal limits. Our differential included iris coloboma, especially since his grandmother reportedly had a similar finding.



Hypertrichosis?



Matthew Feng, MD, & Thiri Pugazhendhi, MD, test their penlights before clinic.

Salud Juntos Staff of the Day

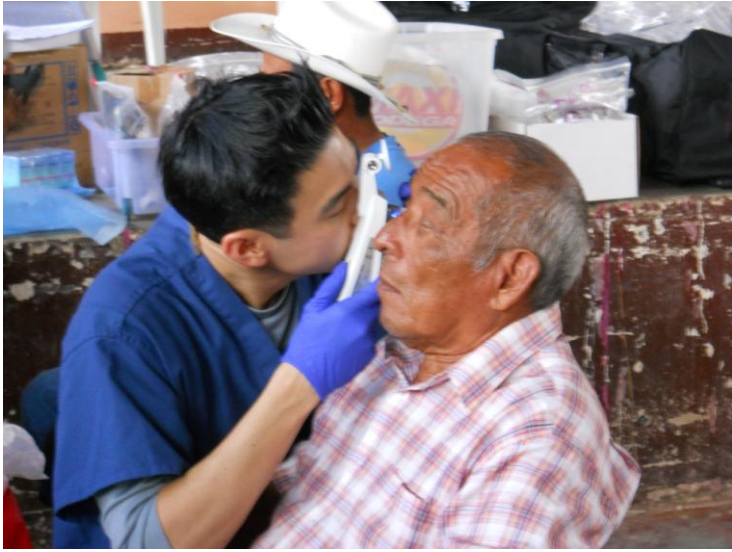

Flor Cruz, age 17, a high school student from Yoro, is a volunteer for the eye brigade. She takes the history, performs the vision test, and distributes glasses to the patient. This is her second year volunteering at the eye brigade in Punta Ocote. Flor would like to become a professional nurse, and two years ago took some professional health care courses in San Pedro Sula, and plans to take the nurses' exam next year. She became interested in volunteering because she loves to help people.

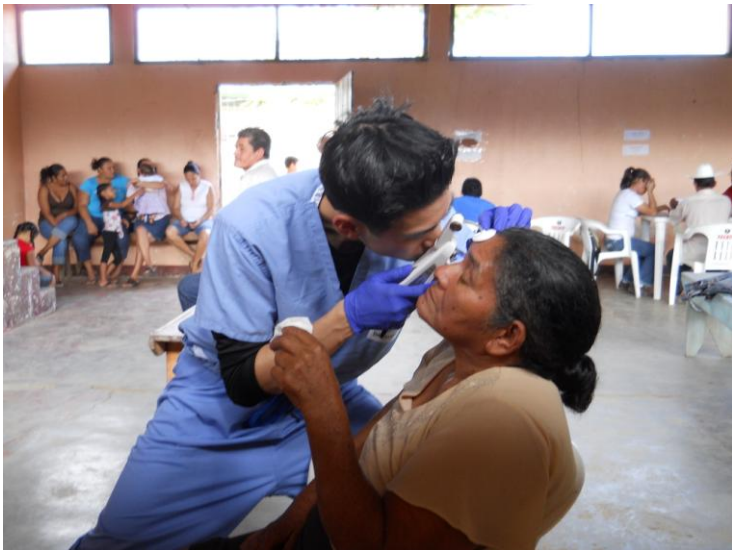

Thiri finds vegetarian heaven... at last!...at a Chinese restaurant...Whowuddathunkit!

How Do You Perkins?



The wrong way to use a Perkins tonometer to check intraocular pressure.



Matthew demonstrates the right way. Note the position of the forehead support. The deep lunge is optional.

Random Pic of the Day



Self-explanatory.

The New Clinic



The Honduran Ministry of Health recently took possession of the new Punta Ocote clinic, an approximately 1800 square foot steel and concrete structure containing a pharmacy, general purpose room, and three examination rooms. It is staffed nearly daily by two Health Ministry nurses, and the majority of the funding (60%) was provided by the Salud Juntos partnership.



Joe Miller + Hammock = Happy



Joe Miller – Hammock = Not So Happy

Pat Broyles, Turkey Stalker



Today, Pat graduated from chickens and moved on to bigger fowl. Her sidekick/apprentice is Thiri.

Turkey of the Day

Chicken of the Day



Geocache of the Day



Hotel Marquet, Yoro, Yoro, Honduras
N 15 degrees 08.444'
W 87 degrees 07.660'

Tuesday Stats

Of the 55 patients seen, 19 (35%) were men and 36 (65%) were women.

Age	Hyperopia	Emmetropia	Myopia
<= 40 yrs	6	7	1
>40	35	3	0

Diagnoses:

- 37 REFRACTIVE ERROR
- 33 DRY EYE
- 25 ALLERGIC CONJUNCTIVITIS
- 21 CATARACT
- 14 PTERYGEA
- 5 DIABETIC WITHOUT RETINOPATHY
- 3 CONJUNCTIVAL NEVUS
- 2 EPIRETINAL MEMBRANE
- 1 NORMAL TENSION GLAUCOMA SUSPECT
- 1 OCULAR HYPERTENSION
- 1 CHOROIDDAL NEVUS
- 1 CONGENITAL ESOTROPIA
- 1 HYPERTENSIVE RETINOPATHY
- 1 DRUSEN
- 1 IRIS COLOBOMA
- 1 SYMPATHETIC OPHTHALMIA
- 1 CHALAZION
- 1 LAMELLAR HOLE
- 1 ALTERNATING EXOTROPIA